Cardiac MR Imaging and Heart Chamber Segmentation

TEAM B (박현욱 교수님 연구실)
KAIST Last Wednesday Forum
Apr. 26, 2017

Cardiac Magnetic Resonance Imaging

- Magnetic resonance imaging (MRI)

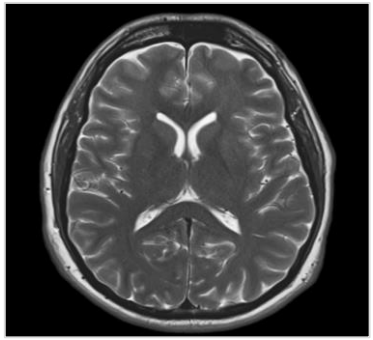

Brain

Abdomen

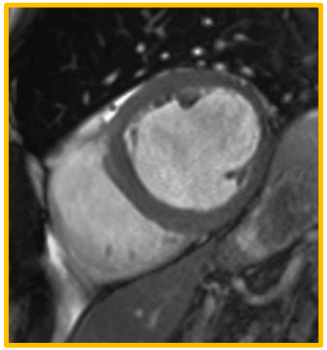

Heart

Vessel

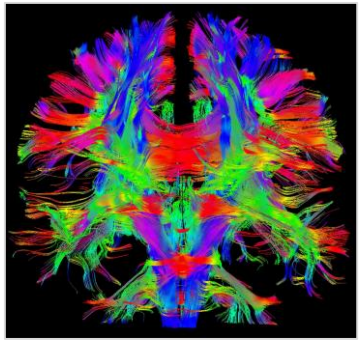

Diffusion

- Non-invasive
- No radiation
- Various contrasts

Cardiac MRI (CMRI)

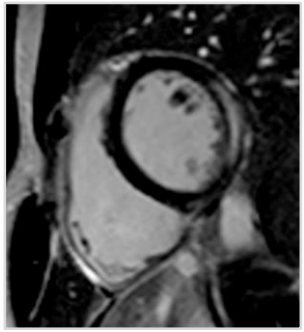

T1

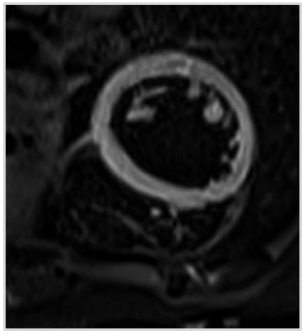

T2

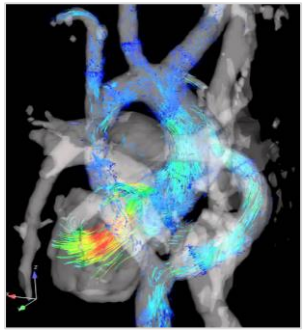

Blood flow

Cardiac Magnetic Resonance Imaging

- Concept of proposed method
  - Cardiac MR imaging and heart chamber segmentation

Data acquisition

- Cardiac cine imaging
  - ✓ Heart morphology
  - ✓ Heart function
  - ✓ Tissue characteristic

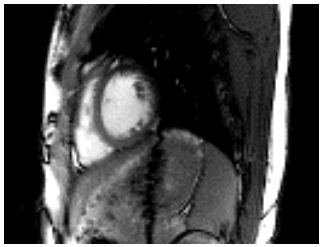

Short axis view

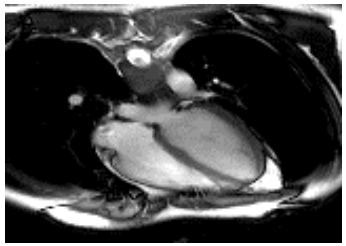

4 chamber view

Post processing

- Heart chamber segmentation
  - ✓ Quantitative analysis
  - ✓ Blood flow amount

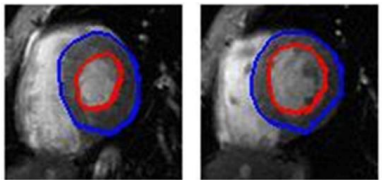

2D segmentation

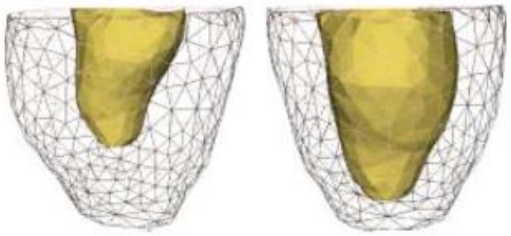

3D segmentation

Cardiac Cine Imaging

- Limitations of MRI
  - Cardiac and respiratory motions

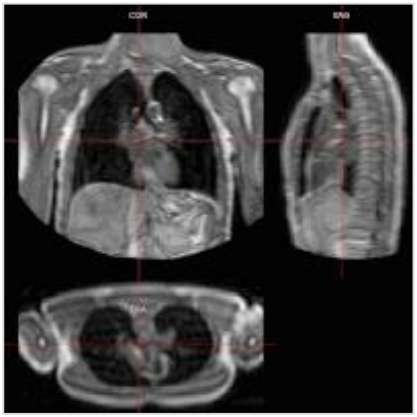

Motions

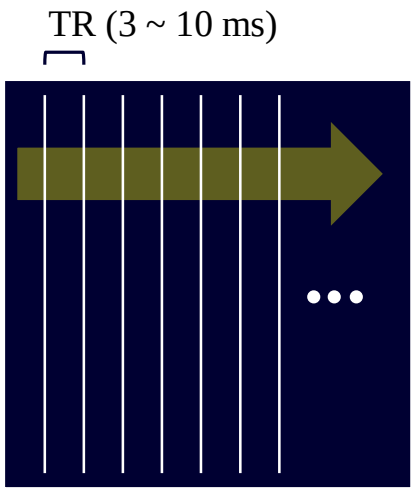

k-Space

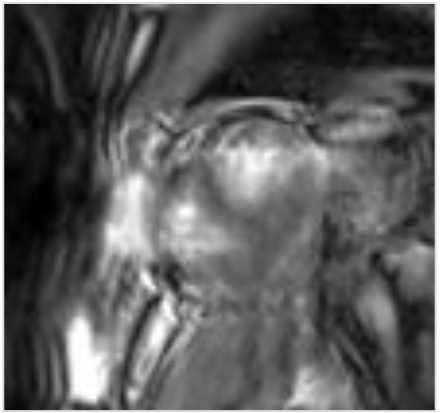

With motions

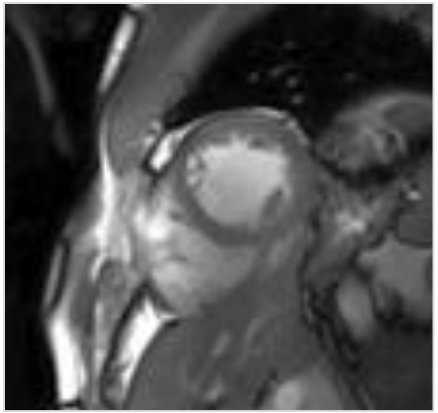

Without motions

Cardiac Cine Imaging

- Conventional method 1
  - Electrocardiogram(ECG) and breath-hold

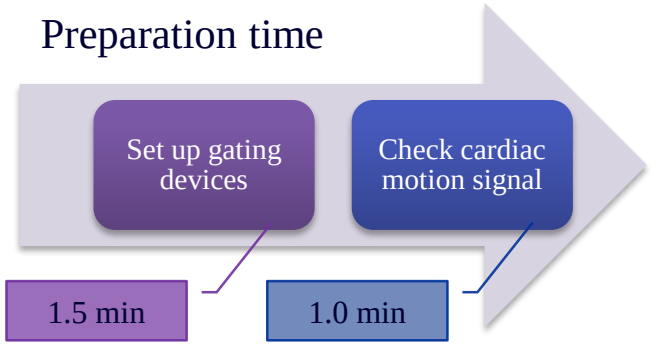

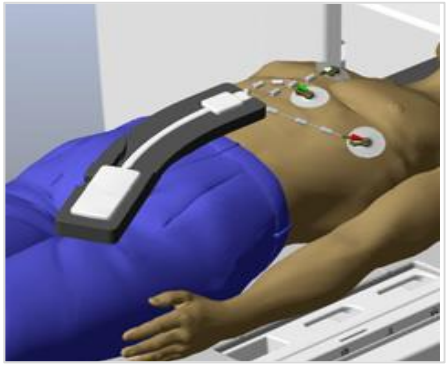

✓ Limitation

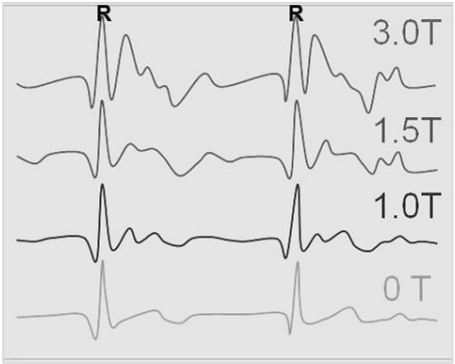

High field effect

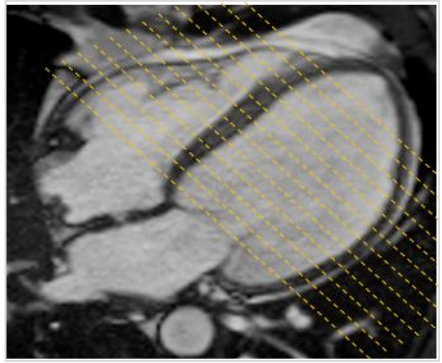

Multi-slice imaging

Coma

Cardiac Cine Imaging

- Conventional method 2
  - Navigator technique
    - ✓ Interleaved acquisitions of MR signals

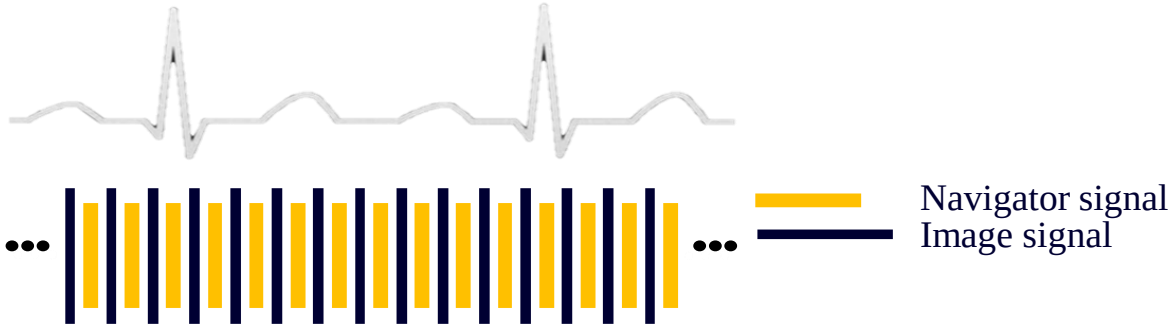

    - ✓ Projection data – a center line of k-space

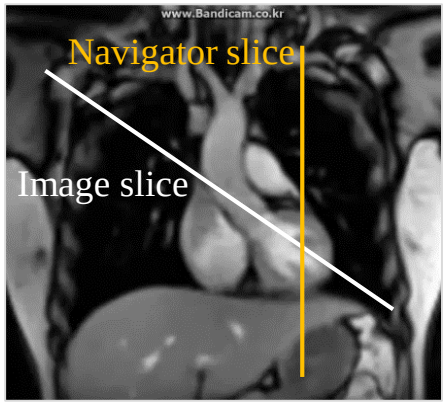

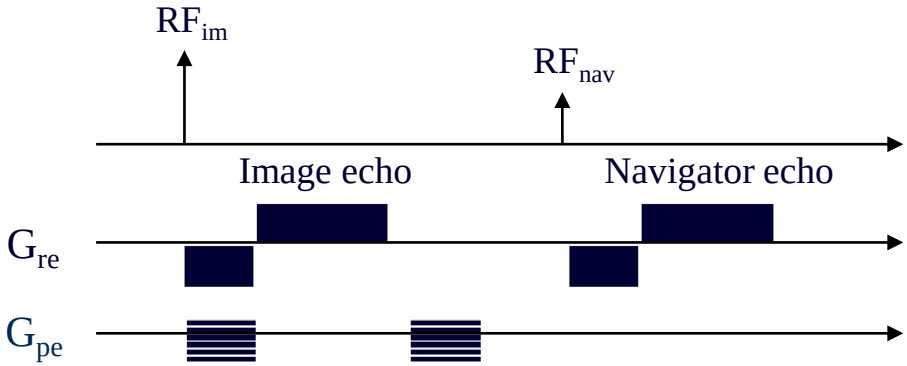

Concept of Proposed Cine Imaging

- Cardiac and respiratory motion correction in CMRI
  - Improved navigator technique

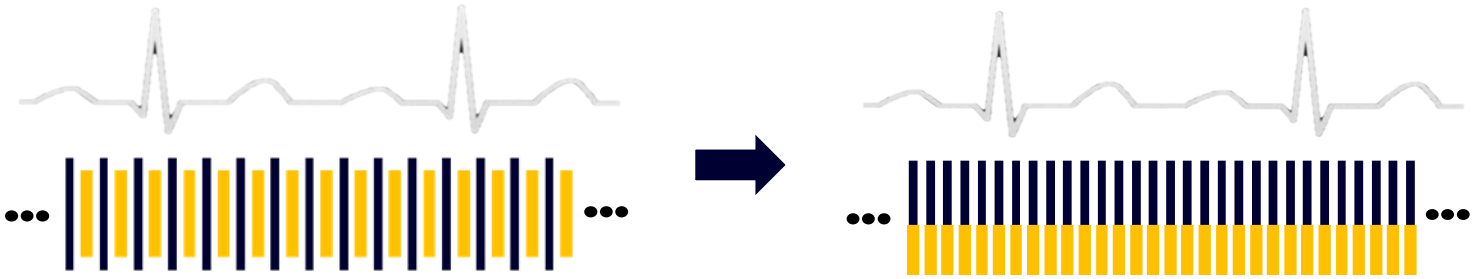

Interleaved acquisition Simultaneous acquisition

✓ High efficiency of scan time
✓ Without external devices and breath-hold

- Separation by using alternating RF phases

$$S_{acq}(k_x,k_y) = S_{im}(k_x,k_y) + S_{nav}(k_x,0)e^{j\pi k_y}$$

$$F^{-2}_{k_x,k_y}[S_{acq}(k_x,k_y)] = I_{im}(x,y) + p(x)\cdot\delta(y-\frac{N}{2})$$